

*Faculty Advisors: Michael Porter, M.D. (NRH US Director, Attending-Core Faculty), Angela Carrick, D.O. (APD NRH EM Program, Attending- Core Faculty) Rachelle Haning, D.O. (EM PGY-4), Kaya Smith, D.O. (EM PGY-3), Spencer Baird, D.O. (EM PGY-3)*

## IMPORTANCE

Yearly, an estimated 300,000 adults older than age 65 are hospitalized with hip fractures in the United States. Studies have suggested that regional pain blocks may help reduce the amount of opiate medication needed to control pain [1]. Thus, can lessen the side effects of opiates in the elderly population who are especially susceptible to the adverse side effects such as delirium, decreasing respiratory drive which leads to pulmonary complications, etc [1]. Ultrasound-guided fascia iliaca blocks (UFIB) in the setting of hip fractures may help improve a patient's pain control leading to better patient satisfaction and outcomes. In 2018 our community hospital added the use of ultrasound-guided fascia iliaca blocks in the ED for hip fractures as an indicator and we started tracking the use [2].

## OBJECTIVES

Utilize a fascia iliaca nerve block in all eligible patients presenting to Norman Regional Emergency Department with acute hip fracture.

## METHODS

In order to increase the utilization of UFIB, education was provided at both the resident didactic meetings and during our monthly hospital emergency department staff meetings to all EM attendings and EM residents. Education included educating physicians on why UFIB could help improve a patient's pain and overall outcomes (evidence given through literature review), inclusion and exclusion criteria which includes obtaining informed consent from all eligible patients (or the patient's medical power of attorney), step by step approach to how to perform the procedure, thorough review of sonographic anatomy, the recommended medication mixture for the procedure to provide the longest amount of analgesia. Additionally, UFIB kits were designed for quick access to the needed materials. Major complications were tracked by our hospital's hip fracture program. This was compared with our utilization trend of UFIB. Retrospective chart review was performed for adverse reactions to the UFIB procedure.

## US Guided Fascia Iliaca Block

### Inclusion Criteria

- Proven hip fracture on imaging
- Patient or POA must consent for the procedure

### Exclusion Criteria

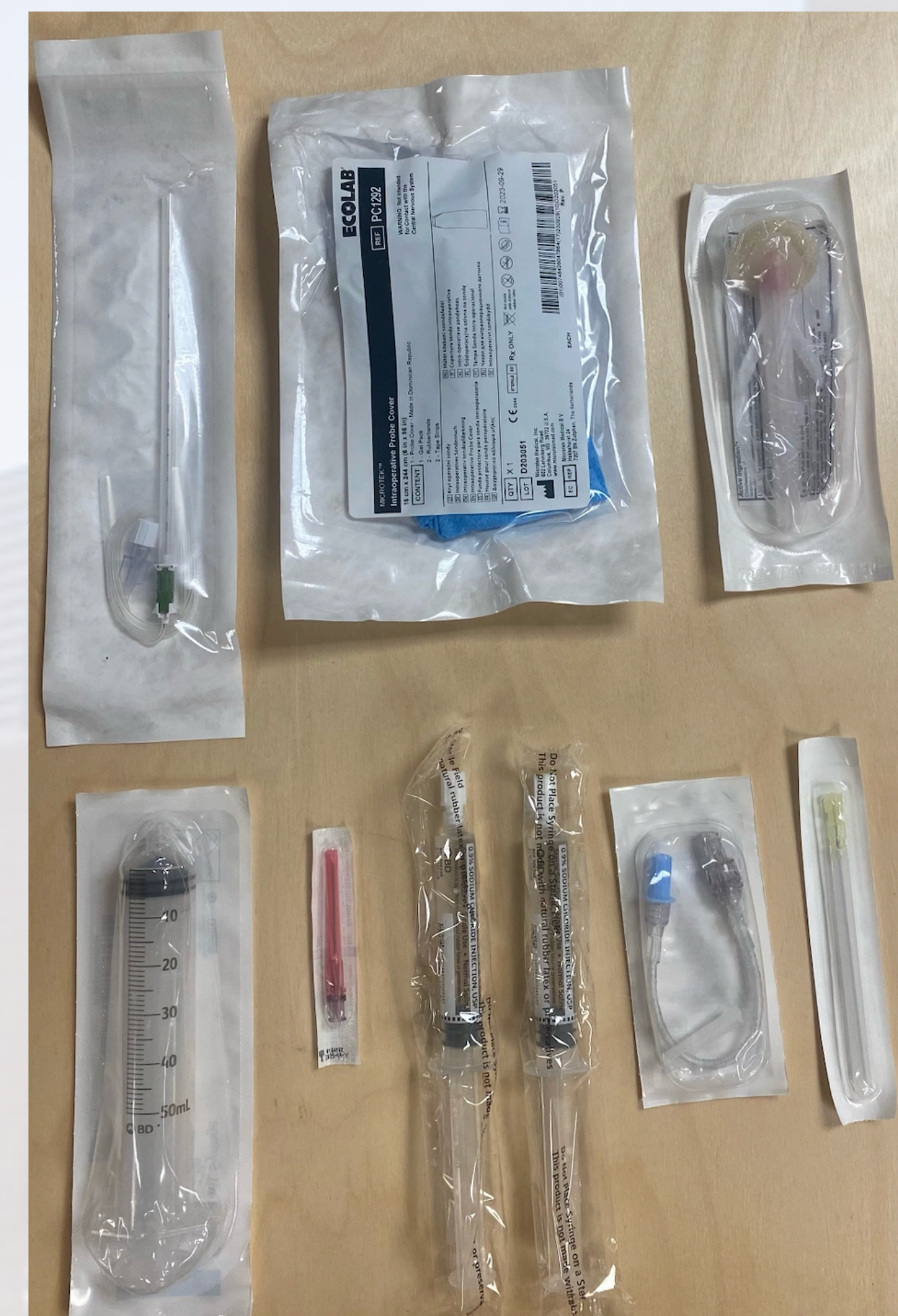
- Patient or POA declines procedure
- Fall was >24 hours prior to ED admission
- Known allergy to medication
- Injection site infection
- Abnormal neuromuscular exam (decreased pulses, sensation, reflexes)
- Physician documentation on why pain block is not appropriate

### Recommended Anesthetic Mixture for Patients >55kg

30 mL (150mg of 0.5% Ropivacaine) + 20 mL of normal saline (+/- 2mg Decadron) = 50 mL

\*Maximum dose of 2.86 mg/kg for Ropivacaine (Always calculate max dose before procedure)

\*Adding dexamethasone can increase duration of analgesia [3]

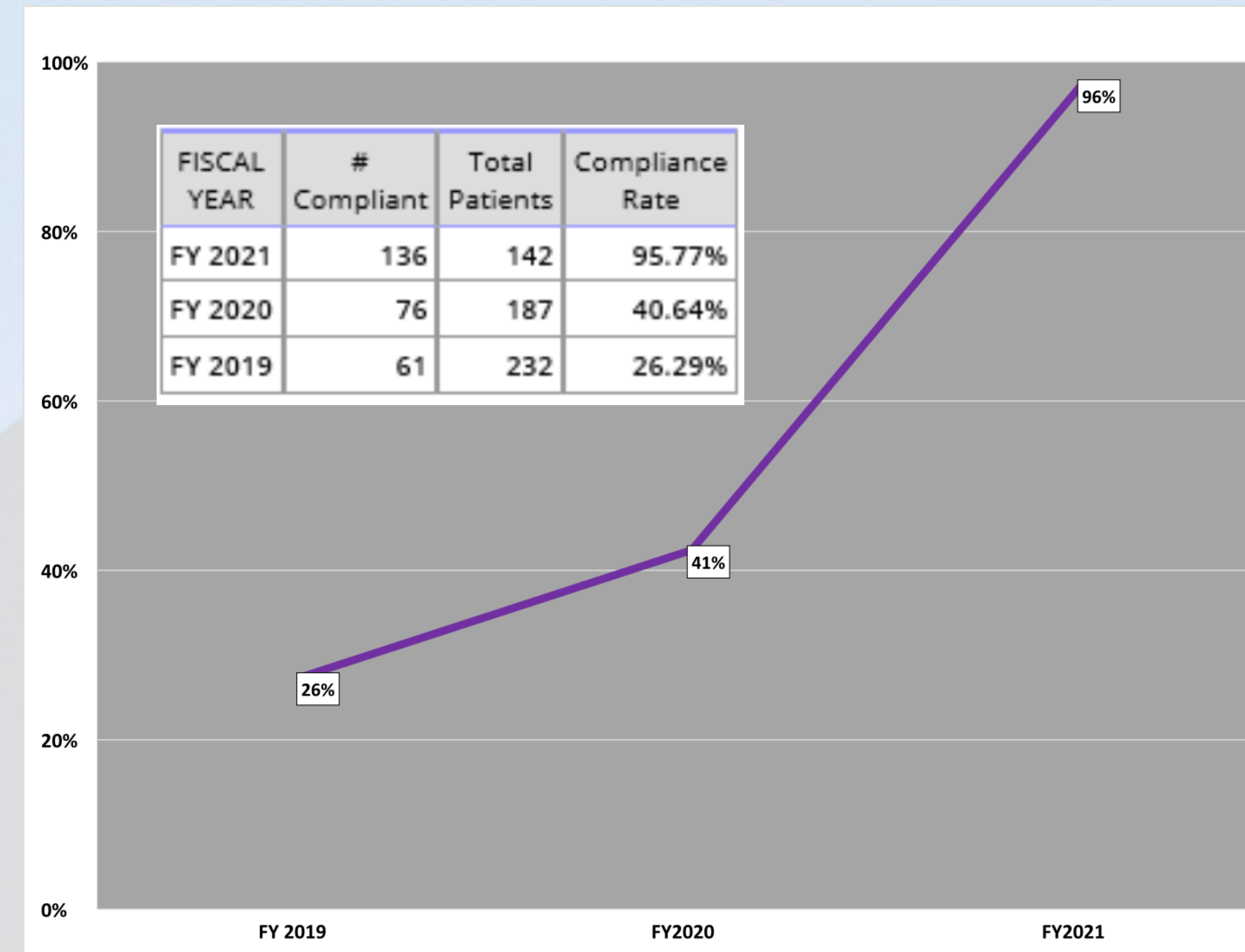


**Figure 1 : Hip Block Kit**

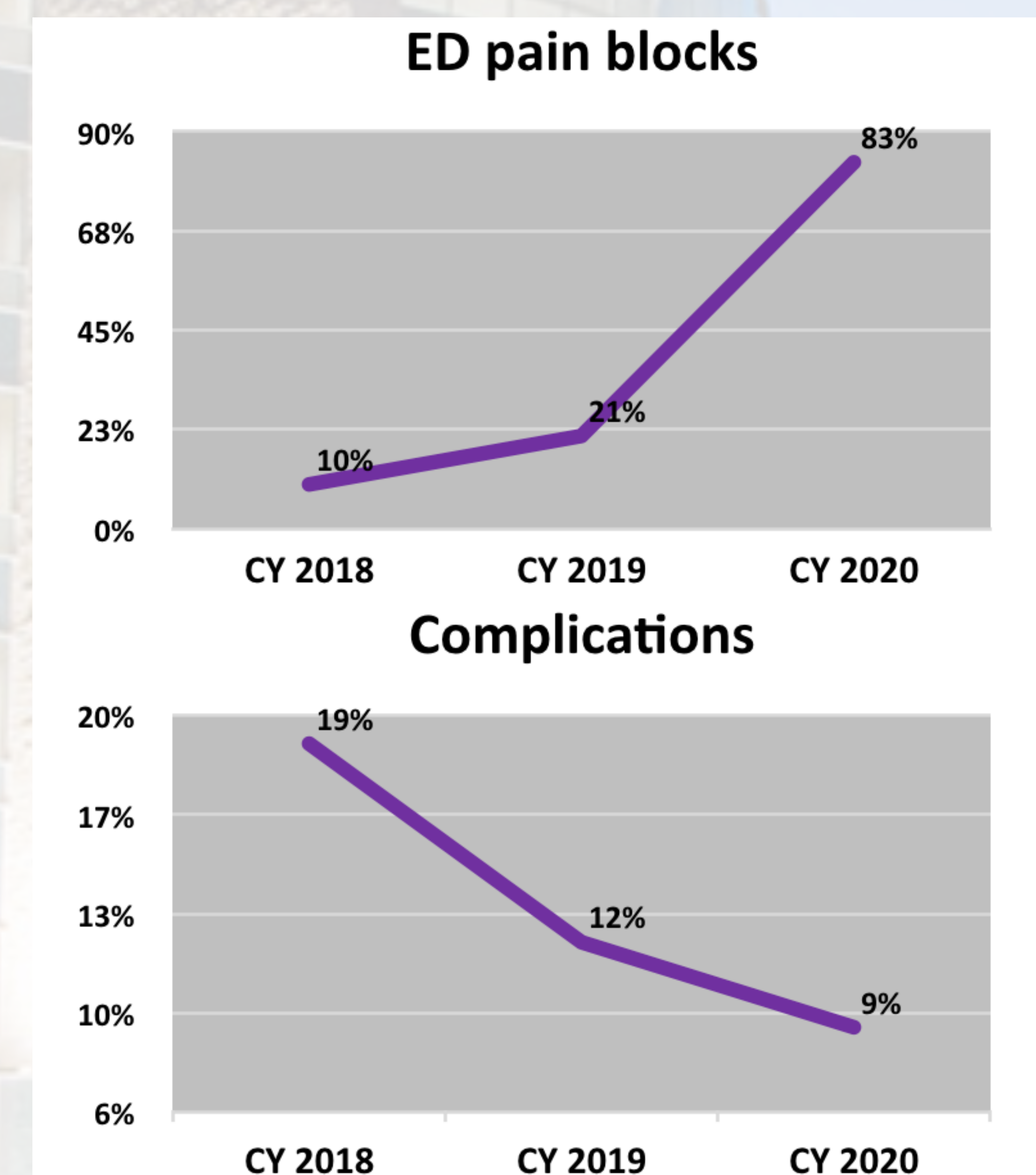
Shows what our hip block kit consists of a 50cc locking syringe, SonoTAP 21 gauge needle, blunt filter needle, sterile US probe cover, 10cc normal saline flushes, chlorhexidine prep, (Alternative needle is also pictured with IV connector)

## RESULTS

Utilization of hip blocks were tracked by fiscal year. In 2019, utilization compliance was 26.29%. A short discussion without a visual powerpoint presentation was given in January 2019 at the ED monthly department meeting discussing how and why we implemented ultrasound-guided fascia iliaca blocks in the emergency department, this discussion was given by an ED resident physician. Otherwise, in 2019 education on how to perform the procedure was mostly through shift learning in



**Figure 2 :** Shows compliance rate of fascia iliaca blocks per fiscal year



**Figure 3 :** Shows ED fascia iliaca performance trend compared to hip fracture major complication trend per calendar year

which an ED attending, who was already proficient in the procedure, demonstrated the procedure to the learning ED attending and ED residents on shift. In 2020, utilization increased to 40.64%. UFIB education during the year 2020 FY was somewhat limited secondary to multiple factors, including the COVID-19 pandemic.

## RESULTS, cont.

However, most education was still done through on-shift learning. At the end of 2020 FY and beginning of 2021 FY, we did begin implementing our quality improvement measures discussed above and in October 2020, there was a formal lecture powerpoint presentation that was given at both the ED monthly department meeting and during resident didactics. This education included everything discussed in the methods. We also started building hip block kits available at both campuses. The utilization for the 2021 FY was 95.77%. Retrospective chart review was also performed and found that there were no adverse reactions to the UFIB procedure (in 2021 FY).

Additionally, as part of our hip fracture program, major complications (respiratory complications, cardiac complications, delirium, etc) were tracked separately in our hip fracture population which showed a decrease in major complications rates in comparison to an uptrend that was observed in the utilization of fascia iliaca blocks in a 3 year time period.

## CONCLUSION

In our community ED, US-guided fascia iliaca blocks are now offered to all adult patients with radiographic evidence of hip fractures, unless the patient met exclusion criteria. By providing relatively brief training to our emergency physicians and emergency medicine residents and quick access to the needed materials, UFIB can provide effective and safe analgesia to patients and help lessen the complications associated with opiate pain medications. This quality improvement project shows that UFIB can be feasibly implemented in the emergency medicine practice.

## REFERENCES

- 1] Pedersen SJ, Borgbjerg FM, Schousboe B, Pedersen BD, Jørgensen HL, Duus BR, Lauritzen JB; Hip Fracture Group of Bispebjerg Hospital. A comprehensive hip fracture program reduces complication rates and mortality. J Am Geriatr Soc. 2008 Oct;56(10):1831-8. doi: 10.1111/j.1532-5415.2008.01945.x. PMID: 19054201.
- 2] Beaudoin FL, Haran JP, Liebmann O. A comparison of ultrasound-guided three-in-one femoral nerve block versus parenteral opioids alone for analgesia in emergency department patients with hip fractures: a randomized controlled trial. Acad Emerg Med. 2013 Jun;20(6):584-91. doi: 10.1111/acem.12154. PMID: 23758305.
- 3] Sherif AA, Elserly HE. Dexamethasone as adjuvant for femoral nerve block following knee arthroplasty: a randomized, controlled study. Acta Anaesthesiol Scand. 2016 Aug;60(7):977-87. doi: 10.1111/aas.12750. Epub 2016 Jun 3. PMID: 27255560.